

## Asymptomatic active Paget bone disease: a case report

Maryam sahebari<sup>1</sup>, Behzad Aminzadeh<sup>2</sup>, Omid Shahpari<sup>3</sup>, Ramin Ghiyasi Moghaddam<sup>4</sup>, Morteza Safikhan<sup>1</sup>

<sup>1</sup>Rheumatic Diseases Research Center, Mashhad University of Medical Sciences, Mashhad, Iran. <sup>2</sup>Department of Radiology, School of Medicine, Mashhad University of Medical Sciences, Mashhad, Iran. <sup>3</sup>Orthopedic Research Center, Ghaem Hospital, Mashhad University of Medical Sciences, Mashhad, Iran. <sup>4</sup>Bohlol Hospital, Gonabad University of Medical Sciences, Gonabad, Iran.

Paget's disease (osteitis deformans) of bone is a focal skeletal disorder that can be mono- or polyostotic. Paget's disease might be asymptomatic as with normal biomarkers, or it can be symptomatic such as bony enlargement or deformity. The diagnosis can be made by laboratory findings and specific findings in radiology or radionuclide scan, and it is sometimes confirmed by bone biopsy.

In this report, we present the case of a 37-year-old man whose initial symptoms indicated sacroiliitis, which led to the suspicion of ankylosing spondylitis. Following other diagnostic evaluations and based on imaging features and bone biopsy, active Paget's bone disease without abnormal biochemical markers was diagnosed. The laboratory diagnosis tests were normal. Other biomarkers including procollagen type I N-terminal propeptide (PINP), serum C-telopeptide (CTx), urinary N-telopeptide (NTx), and urinary hydroxyproline, are not routinely checked.

The patient also showed a coincidence of unilateral idiopathic gynecomastia. A single dose of 5 mg of zoledronic acid intravenously was prescribed, and the patient was followed for six months.

Paget's bone disease can occur without any change in biochemical markers. In such cases, the response to treatment can be controlled by improving the clinical picture or evaluating the correct imaging findings.

**Keywords:** Asymptomatic, Biomarkers, Osteitis deformans, Paget's disease of bone, Sacroiliitis

### Introduction

Paget's disease of bone (PDB), also known as osteitis deformans, is a skeletal disorder that can be monostotic or polyostotic. In PDB, the bone's osteoblastic activity increases following the acceleration of osteoclast activity, which leads to the formation of bone with many arteries. This causes deformed bones, pain, and pathological fractures [1, 2]. Other clinical manifestations of this disease include osteoarthritis, neurological complications, and deafness, and more involvement in the bones of the skull, spine, arms, legs, and pelvis [3]. PDB is more common in people over the age of 50 and is rarely seen in younger people. It is more prevalent in men and more common in England, Scotland, Central Europe, and Greece as well as in countries and cities settled by European immigrants, such as Australia, Canada, and the United States [4]. The first case of PDB in South Asia was reported in 1963 in India [5]. PDB is usually diagnosed from increased levels of bone metabolism markers, alkaline phosphatase (ALP), and skeletal involvement confirmed by magnetic resona-

nce imaging (MRI) or computed tomography (CT) [1]. If the disease is asymptomatic, the best way to diagnose and evaluate the degree of skeletal involvement in PDB is to use radionuclide imaging instead of X-rays [6]. A bone biopsy is usually unnecessary, as it increases the risk of fractures and other complications [3].

To aid the diagnosis and rapid initial treatment of PDB treatments, measuring bone proteins and peptides and their products could be beneficial. One such product is ALP [7]. The ALP activity rate is a biochemical marker reflecting bone formation [8]. Measurement of bone alkaline phosphatase (BAP) and total alkaline phosphatase (TAP) is essential in diagnosing PDB [7]. All bone ALP isoforms increase in PDB [9]. Patients whose serum ALP levels are much higher than normal should be treated to balance hypercalcemia to prevent the complications of hypercalcemia. Specialists also recommend antiresorptive therapy to treat patients without typical symptoms, which slows the

Personal non-commercial use only. Rheumatology Research Journal. Copyright © 2021. All rights reserved

\*Corresponding Author: Dr Maryam sahebari, Rheumatic Diseases Research Center, Mashhad University of Medical Sciences, Mashhad, Iran., E-mail: [sahebarim@mums.ac.ir](mailto:sahebarim@mums.ac.ir) Telefax: +98 51 38012753.

**Received:** 10 April 2020; **Accepted:** 12 July 2020

disease progression. Oral and IV bisphosphonates are among the drugs prescribed for PDB [3].

In this report, we present a young man that has been suffering from pelvic pain with severe inflammatory low back pain from a long time ago, and due to the stability of ALP, the diagnosis was delayed.

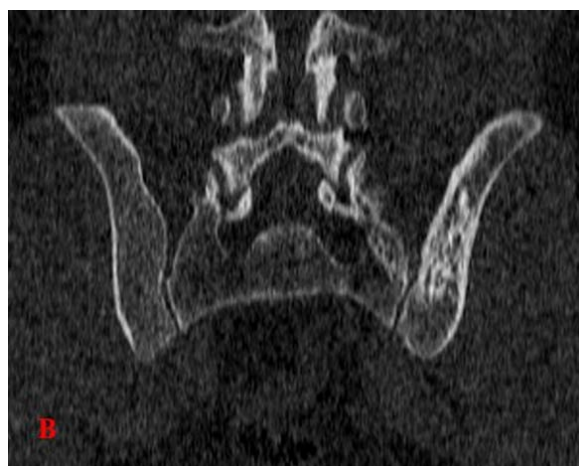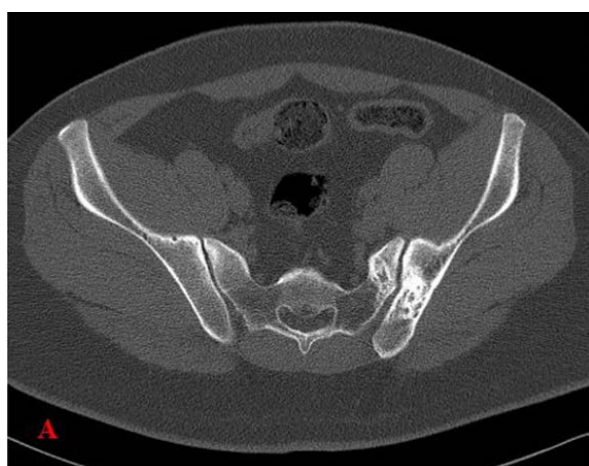### Case presentation

A 37-year-old man with a two-year complaint of bone pain in the pelvis and lower back with several normal imaging results, included radiography CT scan and MRI of the pelvis, and normal laboratory tests was referred for re-evaluation. No abnormal findings except for unilateral gynecomastia and tenderness on the left side sacroiliac joint was observed in the detailed physical examination. In the pelvic examination, the maximum tenderness was on the left side, and the FABER test (Flexion, Abduction,

External Rotation of hip joint) on the same side was positive. The straight leg raising (SLR) test was normal on both sides. Muscle force was normal, and no skin lesion was observed in the patient.

The lab data summarized was normal serum level of calcium = 9.9 mg/dL (normal range: 8.5-10), phosphate = 4.1 mg/dl (normal range: 2-4.5), ALP = 277 IU/L (normal range: 60- 306), parathyroid hormone = 71.3 pg/ml (normal range: 15-65), ESR = 29 mm/h, CRP = 6.6 mg/L (normal range < 10 mg/L), and normal CBC. Culture tests of Brucella, tuberculosis, and HLA B27 PCR were negative.

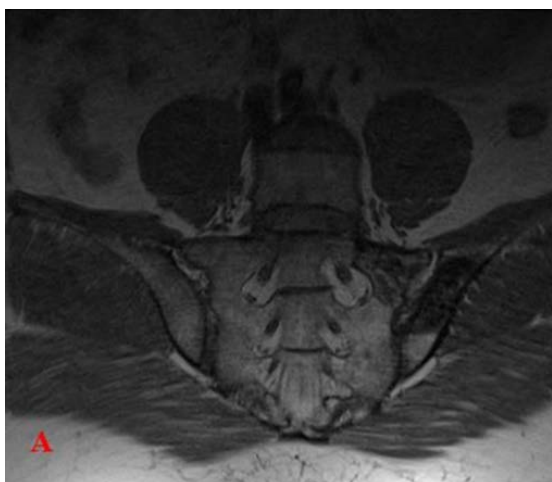
CT scans showed sclerotic changes with uneven trabecular thickening on the left side of the sacrum and iliac bone without left sacroiliac joint involvement, which was in favor of PDB ([Figure 1](#)).



**Figure 1.** Axial (A) and Coronal reformatted (B) CT scan images show Trabecular coarsening and sclerosis of the left Ilium and Sacrum bones with cortical thickening adjacent to the sacroiliac joint

According to MRI, the reduction of the left iliac and sacrum signal in the sacroiliac joint's vicinity indicated sclerotic and degenerative changes, which indicates a

decrease in joint space in the left sacroiliac and sacroiliitis ([Figure 2](#)). Lumbar MRI was normal with no evidence of disc protrusion or canal stenosis.



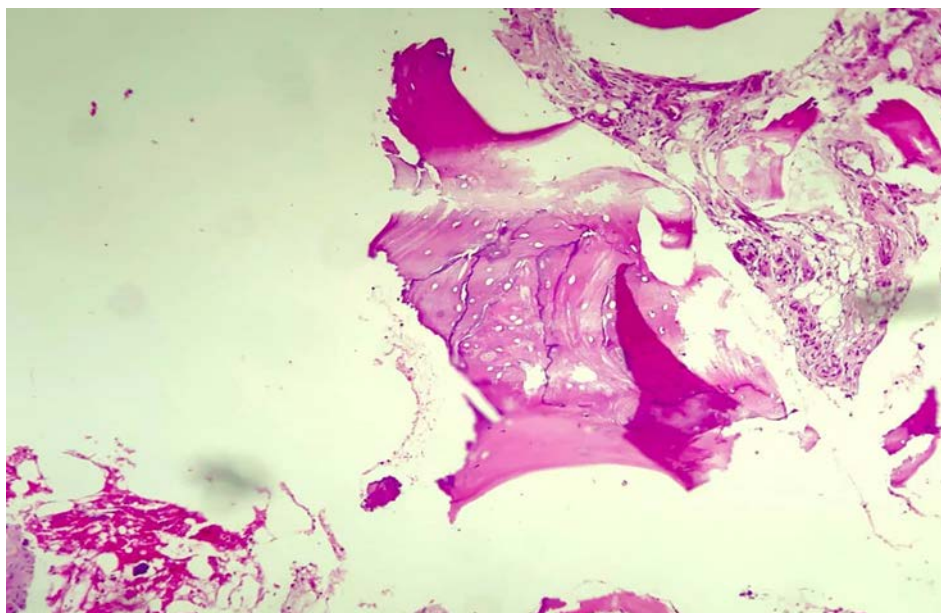
**Figure 2.** Coronal T1w (A) and Stir (B) MRI images show sclerosis of the left Ilium and Sacrum bones with mild bone marrow edema

Everything was normal on the abdominal and pelvic ultrasonography. The patient was evaluated for gynecomastia presenting from the beginning of the sacroiliac pain. The breast biopsy report suggested gynecomastia without evidence of malignancy. The breast ultrasound report only mentioned fibroglandular tissue, suggesting gynecomastia.

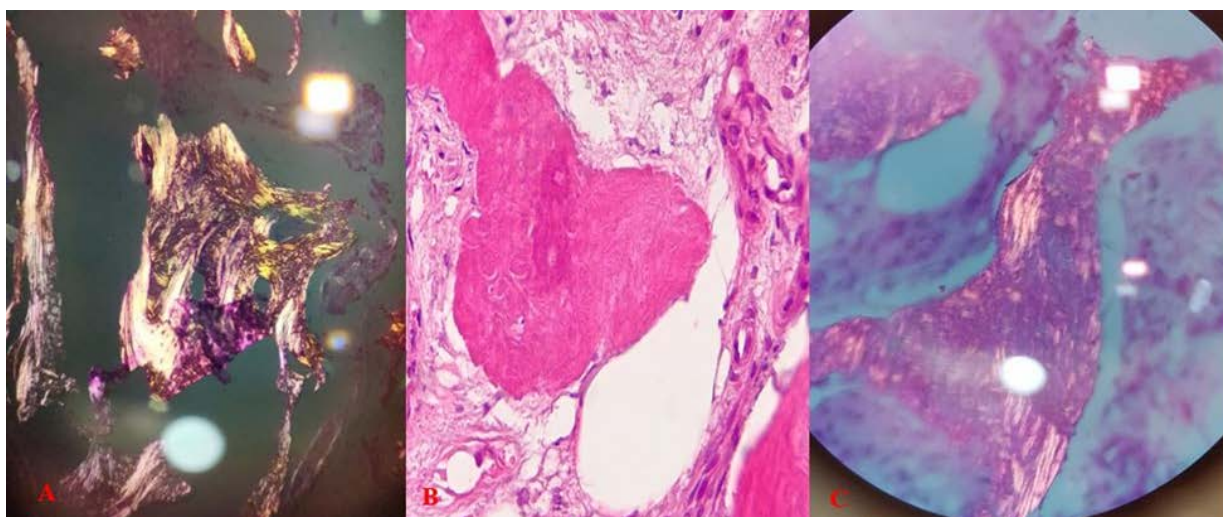
Our patient underwent a bone biopsy because of the absence of abnormal ALP. In microscopic evaluation, sections of bone were found that contained irregular lamellar blades of bone with a clear cement line and fibrous

tissue in between (Figure 3). In the study with polarized light in several small foci mentioned in the field of fibrosis, woven bone blades were sometimes observed with osteoclastic activity in the wall (Figure 4). Based on the patient's available findings, the final diagnosis of PDB was made.

We decided to treat the patient with an intravenous dose of zoledronic acid (Aclasta). One week after the injection, the patient developed flu-like symptoms, which lasted for a few days. The patient's pain improved slightly two weeks after treatment initiation but persists. We continue to follow the patient.



**Figure 3.** fragments of lamellar woven bone with cement lines.



**Figure 4.** (A) lamellar bone in a polarized microscope, (B) fragments of woven bone, (C) woven bone in the polarized microscope.

## Discussion

In this report, we presented a case whose PDB disease was initially known as ankylosing spondylitis based on normal laboratory data and imaging results over several

years. Ultimately, a pelvic MRI, two CT scans, and a bone biopsy assisted us in diagnosing PDB. The patient's young age and the coincidence of unilateral idiopathic gynecomastia were other important features of this case. To the best of our knowledge, there is no report of a coincidence



such as this case in the literature. PDB is more common on the European continent [5] and in older populations, and it causes significant complications. Nonetheless its prevalence appears to be declining in countries with higher numbers of cases [9].

PDB is a disease that has so far been unique to humans and has nothing in common with other diseases. Despite advancements in pathology science and effective treatment, our understanding of its etiology and biology is lacking.

It seems that in addition to genetic factors, environmental ones also play a role in the development of PDB. There is some evidence that the measles virus and canine distemper virus (CDV) transmitted to humans through bites or scratches from infected dogs could be etiologic factors in PDB transmission. There are also hypotheses that toxins such as arsenic or lead are involved in its etiology [10]. The most common bones affected by PDB are the skull, pelvis, sacrum, lumbar spine, femur, and tibia [1]. The disease can affect any bone, but the lower extremities are more involved than the upper limbs, and in the upper extremities the arm and scapula are more modified [11].

The patient in this report suffered from pelvic and lower back pain and stiffness for a long time but had normal imaging and laboratory findings until recently. The course of the disease is divided into three stages: the early destructive stage (incipient active, lytic), predominated by osteoclastic activity; the intermediate stage (active, mixed), osteoblastic as well as osteoclastic activity; and the late stage (inactive, sclerotic/blastoc).

The level of pain depends on the disease's location and the severity of the recurrence. It is usually persistent and present at rest but is not specific. PDB is often accidentally diagnosed by skeletal X-ray when a patient is examined for an unrelated complaint or with an unexplained increase in serum ALP activity [12]. Serum total alkaline phosphatase (TAP) for PDB is a useful biomarker and usually increases during the disease. Historically, increased TAP activity has been one of the diagnosis patterns in patients recently contracting PDB [9]. Diagnosis becomes much more difficult in cases with normal serum ALP. This can occur in the monostotic state of PDB or when a small part of the bone is affected. According to studies, an increase in serum ALP up to 25% higher than nadir, even though TAP is still normal, indicates a significant recurrence of PDB and a 25% decrease in serum ALP indicates a response to treatment [1].

The main treatment for PDB is bisphosphonates. Patients who cannot tolerate bisphosphonates can also receive calcitonin [13]. The efficacy of bisphosphonate therapy on radiologic changes and bone metabolism has been reported in various studies [14]. In PDB patients, drug management based on the use of drugs that reduce bone

biomarkers or bone circulation, significantly inhibiting bone resorption by osteoclasts, is one of the most critical therapeutic points [6].

## Conclusion

Herein, we described a patient with Paget's disease of bone with long-term normal biochemical levels that finally showed pelvic bone involvement through MRI. As in our case, ALP may be normal. In most cases, the disease may be asymptomatic. CT scans and MRIs for better diagnosis and more accurate results are helpful, but the gold standard of diagnosis is a bone biopsy.

Not Applicable.

## Consent for publication

Written informed consent was obtained from the patient to publish this case report and any accompanying images. A copy of the written consent is available for review from the Editor-in-Chief of this journal.

## Availability of data and materials

Not applicable.

## Competing interests

The authors have no competing interests in preparing and submitting this manuscript.

## Funding

This research received no specific grant from any funding agency in the public, commercial, or not-for-profit sectors.

## Acknowledgments

Not applicable.

## Conflict of interest

None.

## References

- Gkouva L, Andrikoula M, Kontogeorgakos V, Papachristou DJ, Tsatsoulis A. Active Paget's disease of bone with normal biomarkers of bone metabolism: a case report and review of the literature. *Clin Rheumatol* 2011; 30(1):139-44. doi:10.1007/s10067-010-1579-z.
- Ang G, Feiglin D, Moses AM. Symptomatic and scintigraphic improvement after intravenous pamidronate treatment of Paget's disease of bone in patients with normal serum alkaline phosphatase levels. *Endocr Pract* 2003; 9(4):280-83. doi:10.4158/EP.9.4.280.
- Abelson A. A review of Paget's disease of bone with a focus on the efficacy and safety of zoledronic acid 5 mg. *Curr Med Res Opin* 2008; 24(3):695-05. doi:10.1185/030079908X260899.
- Valenzuela EN, Pietschmann P. Epidemiology and pathology of Paget's disease of bone—A review. *Wien Med Wochenschr* 2017; 167(1-2):2-8. doi:10.1007/s10354-016-0496-4.
- Sirikulchayanonta V, Jaovisidha S, Subhadrabandhu T, Rajatanavin R. Asymptomatic Paget's bone disease in ethnic Thais: a series of four case reports and a review of the literature. *J Bone Miner Metab* 2012; 30(4):485-92. doi:10.1007/s00774-011-0330-4.
- Muschitz C, Feichtinger X, Haschka J, Kocijan R. Diagnosis and treatment of Paget's disease of bone. *Wien Med Wochenschr* 2017; 167(1-2):18-24. doi:10.1007/s10354-016-0502-x.
- Deftos LJ, Wolfert RL, Hill CS. Bone alkaline phosphatase in Paget's disease. *Horm Metab Res* 1991; 23(11):559-61. doi:10.1055/s-2007-1003752.
- Kaddam IM, Iqbal SJ, Holland S, Wong M, Manning D. Comparison of serum osteocalcin with total and bone specific alkaline phosphatase and urinary hydroxyproline: creatinine ratio in patients with Paget's disease of bone. *Ann Clin Biochem* 1994; 31(4):327-30. doi:10.1177/000456329403100403.
- Magnusson P, Davie MW, Sharp CA. Circulating and tissue-derived isoforms of bone alkaline phosphatase in Paget's disease of bone. *Scand J Clin Lab Invest* 2010; 70(2):128-35. doi:10.3109/00365511003642527.
- Singer FR. Paget's disease of bone—genetic and environmental factors. *Nat Rev Endocrinol* 2015; 11(11):662-71. doi:10.1038/nrendo.2015.138.
- Winn N, Lalam R, Cassar-Pullicino V. Imaging of Paget's disease of bone. *Wien Med Wochenschr* 2017; 167(1-2):9-17. doi:10.1007/s10354-016-0517-3.
- Appelman-Dijkstra NM, Papapoulos SE. Paget's disease of bone. *Best Pract Res Clin Endocrinol Metab* 2018; 32(5):657-68. doi:10.1016/j.beem.2018.05.005.
- Kravets I. Paget's disease of bone: diagnosis and treatment. *Am J Med* 2018; 131(11):1298-03. doi:10.1016/j.amjmed.2018.04.028.
- Grasemann C, Schündeln MM, Hövel M, Schweiger B, Bergmann C, Herrmann R, et al. Effects of RANK-ligand antibody (denosumab) treatment on bone turnover markers in a girl with juvenile Paget's disease. *J Clin Endocrinol Metab* 2013; 98(8):3121-26. doi:10.1210/jc.2013-1143.