

Immune-mediated necrotizing myositis following SARS-Cov-2: A case report

Soraya Shadmanfar¹, Golamhossein Alishiri², Ramezan Jafari³, Esmat Davoudi-Monfared^{4*}

¹Health Research Center, Life style institute, Department of Rheumatology, Baqiyatallah University of Medical Sciences, Tehran, Iran. ²Chemical Injuries Research Center, Department of Rheumatology, Baqiyatallah University of Medical Sciences, Tehran, Iran. ³Health Research Center, Department of Radiology, Baqiyatallah University of Medical Sciences, Tehran, Iran. ⁴ Health Management Research Center, Department of Community Medicine, Baqiyatallah University of Medical Sciences, Tehran, Iran.

A 56-year-old woman who had been coughing for 7 weeks was brought to the hospital on April 21, following the sensation of weakness in her lower extremities, then in her upper extremities, and a gradual increase in weakness. Reverse transcription-polymerase chain reaction (RT-PCR) testing of coronavirus disease 2019 (COVID-19) was found to be positive. COVID-19 IgG was also positive. Computed tomography (CT) scan of the chest showed patchy ground-glass opacities in the lungs. Muscle enzymes and aldolase were elevated. Muscle MRI showed defined hyperintensity and edema in proximal muscles. Immunemediated necrotizing myositis was recommended in this patient that may have developed following SARS-Cov-2. Treatment was begun with methylprednisolone pulse and intravenous immune globulin (IVIG). Following the start of treatment, the patient's dyspnea and muscle weakness improved. Although IMNM is a rare condition, especially in SARS-Cov-2, it is rapidly debilitating. Physicians need to be more aware of the clinical and paraclinical features and therapeutic approach of IMNM.

Keywords: COVID-19; Myositis; Necrotizing; SARS-Cov-2

Introduction

Coronavirus has been known to lead to acute respiratory distress syndrome (SARS), Middle East Respiratory Syndrome (MERS), and more recently Coronavirus 2019 (SARS-Cov-2) [1]. The most important manifestations of coronavirus disease 2019 (COVID-19) are respiratory symptoms [2], but severe coronavirus infections have also been associated with headaches, seizures, and stroke [3]; however, there is little evidence of neuromuscular complications [4]. Neuromuscular disorders may have occurred earlier but have been overlapped by systemic manifestations. During the current COVID-19 epidemic, potential neuromuscular complications of the COVID-19 could be Guillain-Barre syndrome, myositis, myopathy, or polyneuropathy [5]. Coronavirus infections may

potentially be associated with myositis. In a recent study on COVID-19 published in China, myalgia or fatigue affected 44%-70% of hospitalized patients, and increased creatinine kinase (CK) was reported in 33% of hospitalized patients [6]. In addition, one-third of patients infected with other coronavirus infections have high levels of CK [7, 8], myalgia symptoms [9], and rhabdomyolysis [10], but myositis has rarely been reported in a variety of coronaviruses [11]. The aim of this study was to introduce a COVID-19 patient with symptoms of necrotizing myositis.

Case presentation

The patient was a 56-year-old female retired teacher living in Tehran who had been coughing since February 24, 2020. She received a dose of penicillin

and a dose of amoxicillin after visiting a doctor, but the cough did not improve. She revisited the doctor and received oral levofloxacin 500 mg/d for five days, which still did not cure the cough. At the same time as coughing, the patient mentioned experiencing dyspnea, especially at night, which worsened whenever she lay down. After one week, the patient felt weakness in her lower extremities and then in the upper extremities. The weakness gradually increased so that she was almost unable to climb stairs and she tired even walking on a flat surface. Neck muscle weakness was added over time. The patient was admitted to the hospital on April 21. The coughing continued during her visit, but it was less frequent. The patient's vital signs at the time of admission were an oral temperature of 37°C, blood pressure 115/70 mmHg, respiratory rate

of 16 per minute, and O₂ sat of 91%. She did not mention a history of fever, weight loss, or dysphagia. In her past medical history, the patient had taken rosuvastatin 10 mg per day for one year and had discontinued it one year ago. She is currently taking a 1-microgram tablet of levothyroxine daily. The patient had no history of contact with a patient with COVID-19, and she had been quarantined before admission. RT-PCR testing of SARS-CoV-2 was performed. CT scan of the lungs showed patchy ground-glass opacities. Muscle enzymes and aldolase were elevated. FANA was positive, and anti-ds DNA was negative. Other tests included Wright, 2-mercaptoethanol (2ME), and hepatitis tests, all of which were negative. Other laboratory test results are given in [Table 1](#).

Table 1: Laboratory tests of patient with necrotizing myositis following SARS-Cov-2

	2020-4-21	2020-4-30	2020-5-6	2020-5-8
WBC (×10³/L)	9600	6500	7400	11300
HB (g/L)	15.1	15.9	14.8	14.1
MCV (fl)	86.3	87	83.7	83
PLT(×10⁶/L)	22200	25400	222000	223000
ESR (ml/h)	51	32	15	
CRP (mg/l)	7.1	5.9	3	
AST (U/L)	243	175		189
ALT (U/L)	247	271		267
ALP (IU/L)	68			
LDH(U/L)	1050	1222		
CPK (U/L)		4624		2140
Aldolase (mU/L)		90		
FANA titer		1:160		
Troponin (ng/ml)		0.040		
PCT (ng/ml)		< 0.03		

On April 27, electromyography (EMG) and nerve conduction velocity (NCV) test revealed the myopathic process in the proximal muscles of the patient, and a muscle biopsy was performed. In the initial H& E frozen incision, muscle atrophy with multiple necrotic degenerative/regenerative fibers was seen as diffuse in the fascicles, and there was no inflammation or fibrosis. The initial diagnosis of necrotizing immune myopathy was made. Ultrasounds of the abdomen and pelvis, kidneys, bladder, spleen, pancreas, liver, and bile ducts, inside and outside the liver and gallbladder, uterus, and adnexa were normal. Lymphadenopathy was not seen around the aorta or neck area. Restrictive patterns were reported in

in spirometry. Muscle MRI showed defined hyperintensity and edema in proximal muscles ([Figure 1](#)). On May 18, RT-PCR testing was reported to be positive, COVID-19 Ig G was positive (Ig G = 1.6), and IgM was negative (IgM = 0.1). Because the patient's respiratory and muscular symptoms had begun 8 weeks prior, Covid-19 IgM was negative, and the patient's cough was better, positive RT-PCR was considered a viral particle (false positive), and the patient's current dyspnea was attributed to respiratory muscle weakness (The patient's pulmonary function test showed a restrictive pattern). Treatment of necrotizing myositis started with methyl-prednisolone pulse 500 mg for three consecutive days and IVIG 20 gr daily for 5 days, followed by prednisolone 1 mg/kg

and azathioprine 2.5 mg/kg. Following the start of no treatment was given.

treatment, the patient's dyspnea and muscle weakness improved. As Covid-19 was not active, no treatment was given.

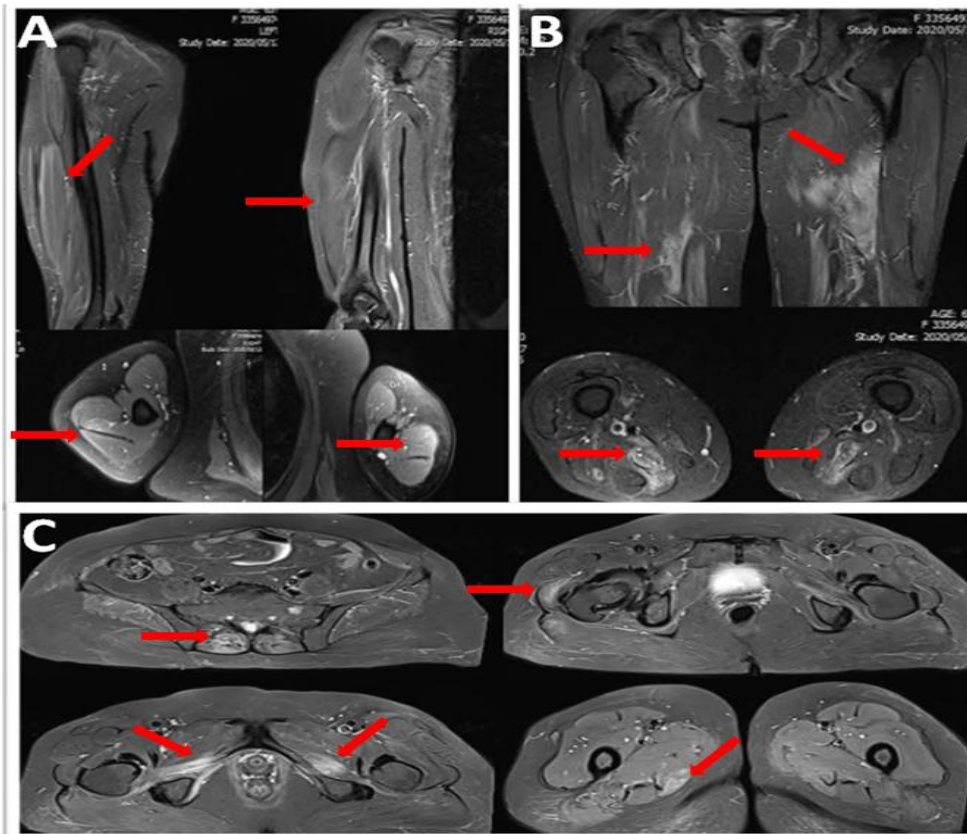


Figure 1: Axial and coronal STIR images from arms (A), thighs (B), and pelvis (C) showed ill-defined hyperintensity and edema in triceps brachii muscles at arms and posterior compartment of thighs, gracilis and semimembranosus, gluteus medius and maximus, obturator externus and spinal muscles bilaterally (red arrows)

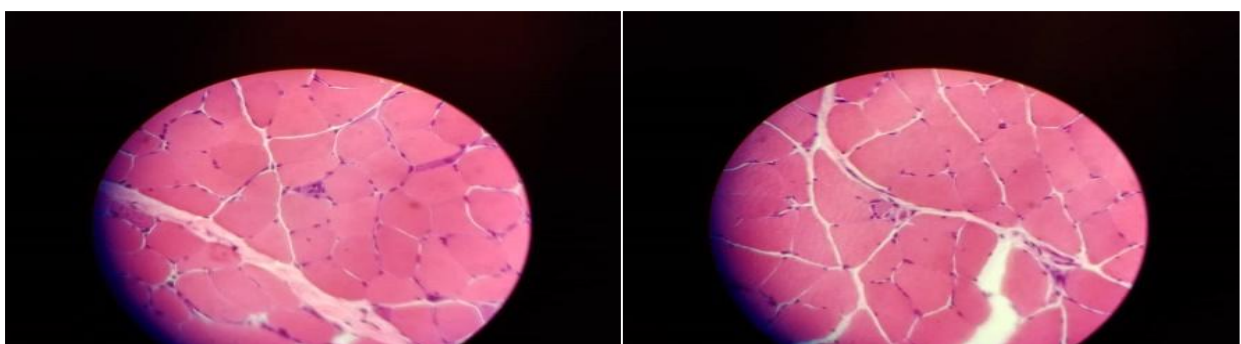


Figure 2: Muscle biopsy demonstrates: Multifocal necrotic and degenerating/regenerating muscle fibers, without inflammation

Discussion

Although myalgia has been seen in several groups of patients with Covid-19 [12] and a prevalence of 11% to 50% for myalgia has been reported by various studies [13,5], myositis is rarely reported in Covid-19[10].In the patient discussed herein,

the manifestation of myositis was seen following Covid-19. To date, Covid-19 has had a variety of manifestations, including neuromuscular ones. Increased creatinine kinase was observed with muscle pain in 10.7% of people with severe

Covid-19 in a Wuhan study [14]. Patients were mostly older, had comorbidities such as diabetes and high blood pressure, and lacked the usual Covid-19 symptoms, lymphopenia and increased D dimer levels, and reactive protein C. In some infected people, the virus may enter the brain or peripheral nervous system through a systemic or direct entry mechanism (for example, through the olfactory epithelium via the Cribriform plate), as seen in SARS CoV2 [15], but this is not yet proven. The virus may be caused by manifestation through direct infection, molecular mimicry, or systemic inflammatory response [16]. The diagnosis of IMNM is based on clinical findings and targeted testing [17]. According to the current patient's laboratory tests, MRI, EMG-NCV, and muscle biopsy, a diagnosis was made of immune-mediated necrotizing myositis that may have developed following SARS-Cov-2, with the viral infection having been the causative agent and trigger of the patient's myositis. In MRI, findings of extensive muscle edema, atrophy, and fat replacement may strongly suggest inflammatory myositis [18]. Although IMNM is a rare condition, especially in SARS-Cov-2, it is rapidly debilitating [19], so high-dose combination immunosuppression treatment is critical for controlling the myopathic process and inflammation. Physicians need to be more aware of the clinical and paraclinical features and therapeutic approaches of IMNM to prevent severe functional disabilities.

Conclusion

In the reported patient, immune-mediated necrotizing myositis was seen following Covid-19. IMNM is a rare condition, especially in SARS-Cov-2, but because of its disabling process, physicians' awareness of clinical management of IMNM is critical.

Compliance with ethical standards

This survey was approved by the local ethics committee (IR.BMSU.REC.1399.181).

Acknowledgment

Researchers thank the Clinical Research Development Unit of Baqiyatallah Hospital for their guidance and advice related to this study

Conflict of interest

The authors declare that they have no conflicts of interest.

References

1. Petrosillo N, Viceconte G, Ergonul O, Ippolito G, Petersen E. COVID-19, SARS and MERS: are they closely related? *ClinMicrobiol Infect* 2020; 26(6):729-34. doi: 10.1016/j.cmi.2020.03.026.
2. Hassan SA, Sheikh FN, Jamal S, Ezeh JK, Akhtar A. Coronavirus (COVID-19): a review of clinical features, diagnosis, and treatment. *Cureus* 2020;12(3):e7355. doi: 10.7759/cureus.7355.
3. Wu Y, Xu X, Chen Z, Duan J, Hashimoto K, Yang L. *et al.* Nervous system involvement after infection with COVID-19 and other coronaviruses. *Brain BehavImmun* 2020; 87:18-22. doi: 10.1016/j.bbi.2020.03.031.
4. Guidon AC, Amato AA. COVID-19 and neuromuscular disorders. *Neurology* 2020; 94(22):959-969. doi: 10.1212/WNL.0000000000009566.
5. Huang C, Wang Y, Li X, Ren L, Zhao J, Hu Y. *et al.* Clinical features of patients infected with 2019 novel coronavirus in Wuhan, China. *Lancet* 2020;395(10223):497-06. doi: 10.1016/S0140-6736(20)30183-5.
6. Wang D, Hu B, Hu C, Zhu F, Liu X, Zhang J. *et al.* Clinical characteristics of 138 hospitalized patients with 2019 novel coronavirus–infected pneumonia in Wuhan, China. *Jama* 2020; 323(11):1061-69. doi: 10.1001/jama.2020.1585.
7. Fan CK, Yieh KM, Peng MY, Lin JC, Wang NC, Chang FY. Clinical and laboratory features in the early stage of severe acute respiratory syndrome. *J MicrobiolImmunol Infect* 2006;39(1):45-53.
8. Wang JT, Sheng WH, Fang CT, Chen YC, Wang JL, Yu CJ. *et al.* Clinical manifestations, laboratory findings, and treatment outcomes of SARS patients. *Emerg Infect Dis* 2004; 10(5):818–24. doi: 10.3201/eid1005.030640.
9. Tsai LK, Hsieh ST, Chao CC, Chen YC, Lin YH, Chang SC. *et al.* Neuromuscular disorders in severe acute respiratory syndrome. *Arch Neurol* 2004; 61(11):1669–73. doi: 10.1001/archneur.61.11.1669.
10. Chen LL, Hsu CW, Tian YC, Fang JT. Rhabdomyolysis associated with acute renal failure in patients with severe acute respiratory syndrome. *Int J ClinPract* 2005; 59(10):1162–1166. doi: 10.1111/j.1368-5031.2005.00540.x.
11. Beydon M, Chevalier K, Al Tabaa O, Hamroun S, Delettre AS, Thomas M. *et al.* Myositis as a manifestation of SARS-CoV-2. *Ann Rheum Dis* 2020; 80(3):e42.doi: 10.1136/annrheumdis-2020-217573.
12. Chen N, Zhou M, Dong X, Qu J, Gong F, Han Y. *et al.* Epidemiological and clinical characteristics of 99 cases of 2019 novel coronavirus pneumonia in Wuhan, China: a descriptive study. *Lancet* 2020; 395(10223):507–13. doi: 10.1016/S0140-6736(20)30211-7.
13. Guan WJ, Ni ZY, Hu Y, Liang WH, Ou CQ, He JX. *et al.* Clinical characteristics of coronavirus disease

- 2019 in China. *N Engl J Med* 2020; 382(18):1708-20. doi: 10.1056/NEJMoa2002032.
14. Mao L, Jin H, Wang M, Hu Y, Chen S, He Q. *et al.* Neurologic manifestations of hospitalized patients with coronavirus disease 2019 in Wuhan, China. *JAMA Neurol* 2020; 77(6):683-90. doi: 10.1001/jamaneurol.2020.1127.
15. Baig AM, Khaleeq A, Ali U, Syeda H. Evidence of the COVID-19 virus targeting the CNS: Tissue distribution, host-virus interaction, and proposed neurotropic mechanisms. *ACS ChemNeurosci* 2020; 11(7):995-98. doi: 10.1021/acchemneuro.0c00122.
16. Benny R, Khadilkar SV. COVID 19: Neuromuscular manifestations. *Ann Indian AcadNeurol* 2020; 23(Suppl 1):S40-S42. doi: 10.4103/aian.AIAN_309_20.
17. Basharat P, Christopher-Stine L. Immune-mediated necrotizing myopathy: update on diagnosis and management. *CurrRheumatol Rep* 2015; 17(12):72. doi: 10.1007/s11926-015-0548-6.
18. Milone M. Diagnosis and management of immune-mediated myopathies. *Mayo ClinProc* 2017; 92(5):826-37. doi: 10.1016/j.mayocp.2016.12.025.
19. Pinal-Fernandez I, Casal-Dominguez M, Mammen AL. Immune-mediated necrotizing myopathy. *CurrRheumatol Rep* 2018; 20(4):21. doi: 10.1007/s11926-018-0732-6.